

Chapter XV

X-RAY PROPHYLAXIS OF GAS BACILLUS INFECTION

As the value of x-rays in therapy became apparent to many clinicians throughout the country, some were quick to grasp its possibilities in prophylaxis. As a result, x-rays have been used prophylactically to some extent against gas bacillus infection. In our experience and that of others it seems to be extremely effective.

As far as we are aware, use of x-rays in prophylaxis was first attempted by Dr. Howard B. Hunt of the University of Nebraska School of Medicine. Watkins, discussing our report³⁵ at the American Medical Association in Kansas City in 1936, stated that from his observation of cases treated, he felt certain that x-rays could be used successfully in prophylaxis. Experience at that time was too meager to permit conclusions, but since then much has been accomplished and the early predictions of Hunt and Watkins have been fully confirmed.

Our report of 1939³⁰ included a tabulation of the last 100 cases of all kinds treated with the mobile unit at Creighton Memorial St. Joseph's Hospital, nine of these for prophylaxis. Cases at St. Catherine's, the Mercy, the County and other hospitals in the Omaha area have not been tabulated during the past few years, but a great number of patients have received x-ray therapy for prevention of wound infection and gas bacillus infection has not developed under such management.

Regardless of the apparent success of the method, the aforementioned tabulation is not considered significant when the evidence in therapy is so conclusive. Anyone seeking help will be guided by the data included in this text which have accumulated as a result of use of x-rays in therapy. Anyone not seeking information will not be influenced by any number of cases in which gas bacillus infection did not develop after prophylaxis. When x-ray therapy will abort an early case, as it has done repeatedly, how can a case develop during the period of prophylactic therapy? As a rule, gas bacillus infection develops in a patient in the first six to 96 hours after his injury, or in the

same length of time after a surgical procedure like resetting a fracture, an amputation or secondary repair.

As far as is known, no one in the Omaha area has developed a gas bacillus infection after a series of prophylactic treatments extending through the first three days following the injury. Others have had similar experiences. Charbonnet and Cooper³¹ in their report to the New Orleans Parish Medical Society on May 23, 1938, listed eight cases in which x-rays were used with apparent success for prophylaxis. They made the following comment: "We wish to emphasize that gas bacillus infection can be prevented, and with the recent methods offered, not only will many lives be saved, but many limbs as well." Between the time of presentation of Charbonnet and Cooper's paper and its publication in January, 1939, Charbonnet wrote an editorial in *Surgery* in which he strongly recommended the use of x-rays in the prevention of gas bacillus infection.

The first report in the literature of a large number of cases came from Bowen³² of the United States Army Medical Corps who, with the cooperation of the surgical service at the Eighth Corps Area Station Hospital at Fort Sam Houston, San Antonio, Texas, gave prophylactic doses of x-rays to 39 patients and treated another immediately after gas bacillus infection developed. In the last-mentioned case treatment was started so early that it is not possible to tell whether it should be included in the prophylactic group or in the group receiving early treatment. Nevertheless, in the total of 40 cases reported gas bacillus infections developed in two. In one, x-rays were given first nine hours after the administration of antitoxin and again 26 hours later. As Bowen stated:

Prophylaxis was given rather late (9 hours) and was not repeated in 12 hours. Twenty-six hours elapsed between the prophylaxis and gas bacillus therapy. The time factor is very important. Prophylaxis should be given just as early as possible and treatment immediately following the diagnosis of gas infection.

Regarding his second case in which a gas bacillus infection developed, Bowen had this to say:

On account of the patient's condition, x-ray gas prophylaxis was not given until the following morning, 20 hours after injury, when the right leg already gave off the characteristic gas odor and there was considerable avascular necrosis of the exposed tissues. No gas crepita-

effective during the second, third and fourth days, as it is during this time that the onset of the disease is most frequent. This does not mean that x-ray prophylaxis during the first day would not be preferable, but we generally see automobile and other

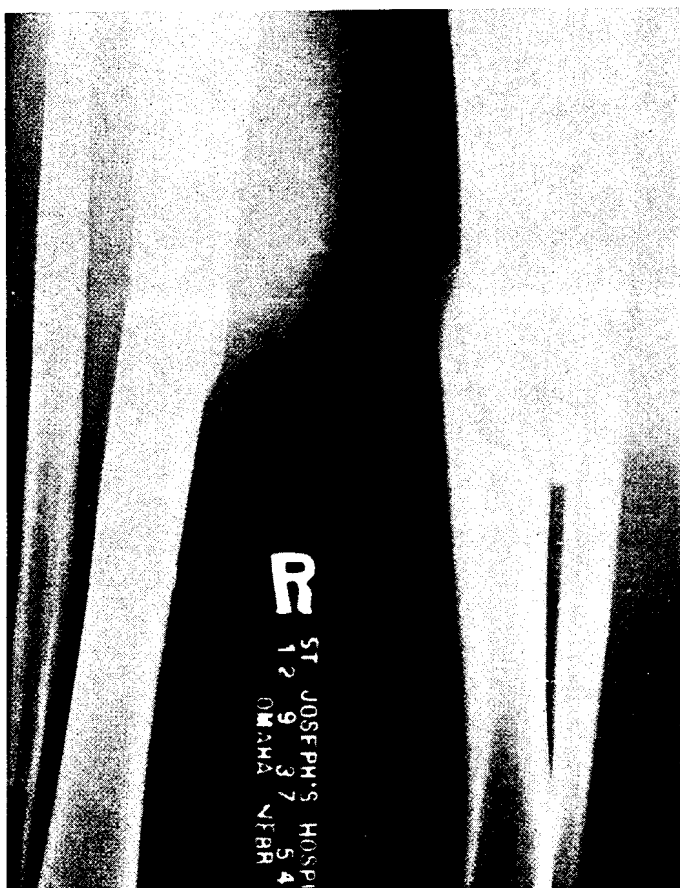


FIG. 35.—Case 14. Complete, compound fracture through middle of shaft of tibia; no infection occurred.

accident cases the second or even the third day after injury, and prophylaxis under those circumstances has been satisfactory. The disease which has its onset the third or fourth day is of relatively low virulence, if the mortality rate in the few cases in this group is maintained when larger numbers become

X-Ray Prophylaxis in Gas Bacillus Infection 201

available for study. Of the 30 cases in which diagnosis was made after the 72 hours, two were fatal, a mortality rate of 6 per cent. This analysis of our material was made at the request of Lt. Col. H. W. Grady and Major A. A. de Lorimier of the United States Army Medical Corps.

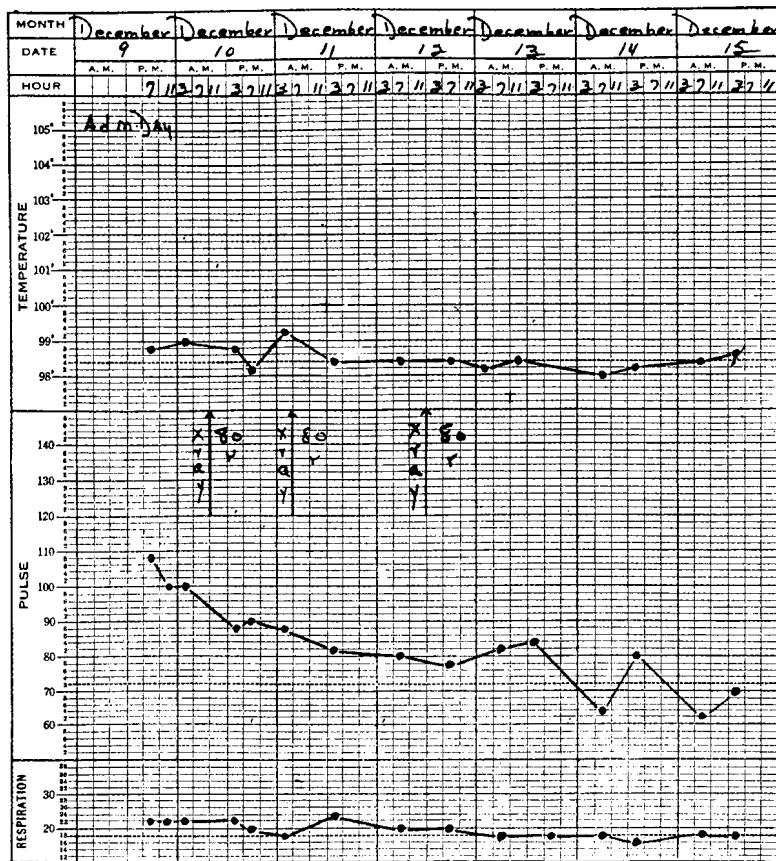


FIG. 34.—Same case as preceding. Technical factors were: 110 kv.; 5 ma.; 50 cm. distance; 3 mm. Al filter; anterior right leg as port. Result was excellent.

CASE 14.—G. K., a youth aged 20, was admitted to the hospital on December 9, 1938, immediately after sustaining a compound fracture of the left tibia (Fig. 33). The wound was débrided and scrubbed with tincture of green soap and sterile water and closed loosely over a soft rubber drain. A plaster cast dressing was applied, with an open window over the site of the external wound. The patient received one x-ray

treatment of 80 r units a day for three days, a total of 240 r units. He showed no evidence of infection (Fig. 34) and the wound healed promptly. New bone formed rapidly around the ends of the fractured bones, and there was firm union so that the patient could use the extremity for weight-bearing after a period of four months (Fig. 35).

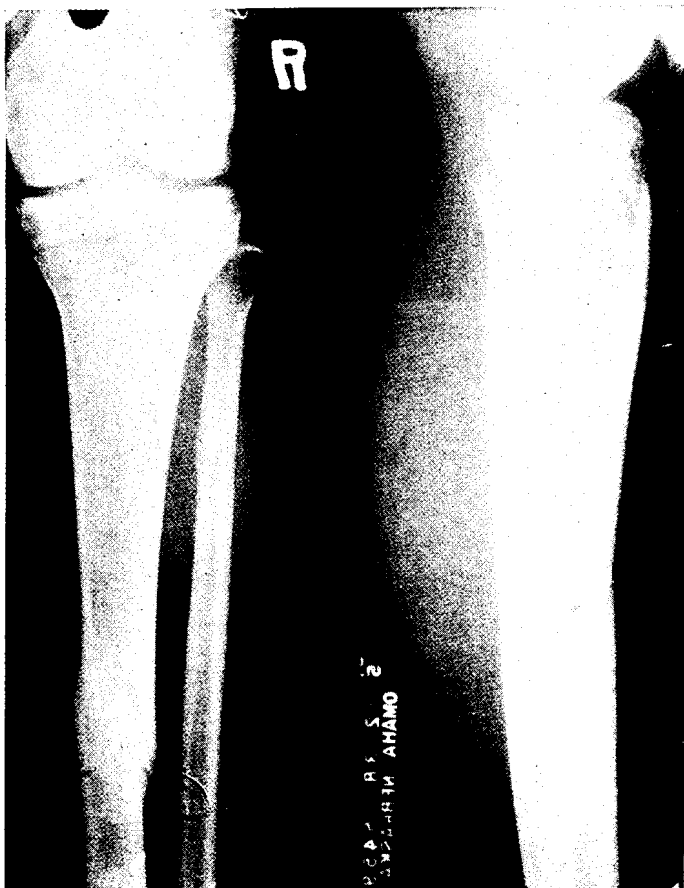


FIG. 35.—Same case as preceding. Complete bony union four months after injury. X-ray therapy given immediately after the injury apparently did not interfere with new bone formation.

Figure 35, showing the character of the union obtained, should encourage those who fear nonunion from the use of x-rays at a fracture site. Extensive débridement or injections of oxidizing or antiseptic solutions are not required. We believe in the early removal of dead tissue or foreign bodies, but not until after the

toxemia subsides and demarcation takes place if a severe infection is present when the patient is first seen.

Figure 34 is of interest because it shows the effectiveness of the method during the period when the disease most commonly develops. In fact, if it develops after this period, mortality is extremely low as the condition is very responsive to treatment.

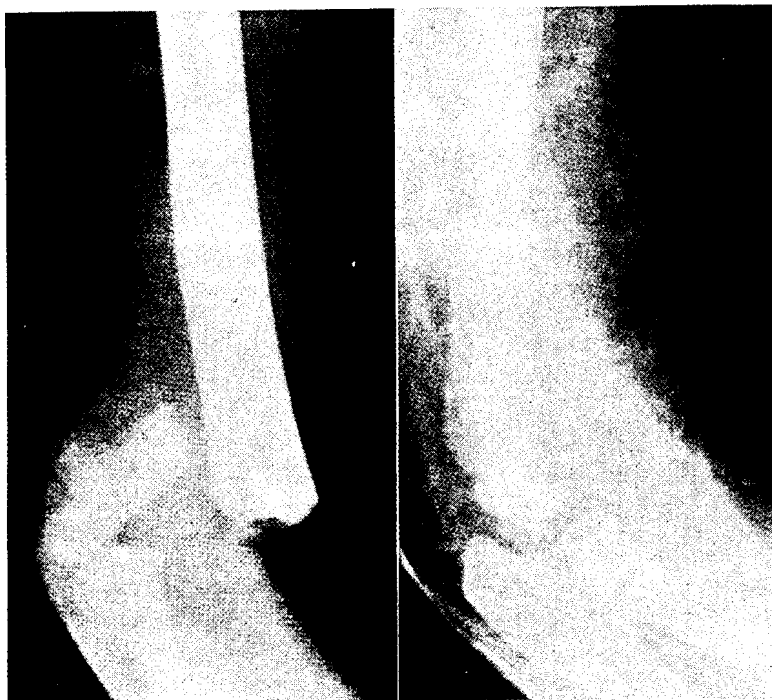


FIG. 36 (left).—Case 15. Common type of fracture of left humerus, occasionally compound, as in this instance, under circumstances highly favorable to infection which would undoubtedly result in osteomyelitis.

FIG. 37 (right).—Same case. Excellent position of fragments. Since there was no infection, the prompt repair resulted in excellent functional recovery.

CASE 15.—F. L., a boy aged 9, entered the hospital about three hours after having been thrown from a horse. He suffered a compound fracture of the lower end of the left humerus with protrusion of the distal end of the fragment (Fig. 36). The soft tissues were severely lacerated. Excellent reduction was obtained, and x-ray therapy was requested as a prophylactic measure. The patient was treated once daily for three days, and was dismissed on the eleventh postoperative day with the wound clean and well healed (Fig. 37).

The value of x-ray therapy in preventing the development of infection in open wounds where there has been considerable damage in the tissues is not sufficiently appreciated. We feel that it assists in a more rapid repair of the soft parts, lessens the number of hospital days and minimizes the danger of infection with gas bacillus and other organisms. X-ray prophylaxis simplifies the treatment, as the surgeon can be more certain of

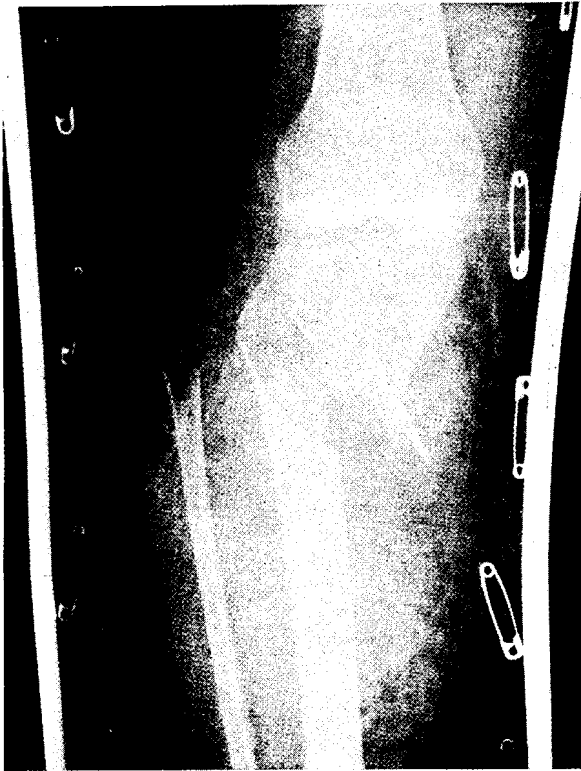


FIG. 38.—Case 16. Comminuted fracture of bones of leg just below the knee.

initial repair and hence primary union. The absence of drainage is one of the advantages. The elimination of fear of a gas bacillus infection makes more complete surgical repair a safe procedure. A closed wound is now good surgical practice if x-ray therapy is used for the following three days.

CASE 16.—M. S., a woman aged 50, was admitted to the hospital on August 14, 1938, with a compound fracture of the right tibia and

fibula and severe lacerations of the soft tissues of the knee. The accident occurred on a downtown street on a rainy night, and the wound was badly contaminated (Fig. 38). She was in shock, and supportive measures were instituted. X-ray therapy was requested as a prophylaxis against gas bacillus infection. She received 10 treatments in the next seven days; no infection developed, but the temperature was definitely elevated. Severed vessels resulted in a gangrenous leg, and amputation was necessary on August 18. She was dismissed September 9. By escaping osteomyelitis, she was able to retain the upper fragments of the tibia and fibula (Fig. 39). The large number of x-ray treatments was given because of the rise in temperature and pulse rate (Fig. 40).

CASE 17 (Courtesy of Drs. A. J. Offerman and H. N. Boyne).—F. E. B., a youth aged 18, while hunting on November 12, 1940, was accidentally shot through the right cheek. The bullet (.22 caliber) entered about 1 in. above the outer angle of the mouth, lacerated the inner mucosa of the cheek about 2 in. and struck the first upper molar; the main fragment lodged in the neck.

Physical examination revealed the right cheek markedly swollen and edematous. There was a small pencil-sized perforation leading into the cheek about 1 in. above and lateral to the right corner of the mouth. The mucosa of the cheek was lacerated and bleeding (Fig. 41).

X-ray films of the facial bones showed two moderate-sized metallic fragments, the smaller lying in the right naso-antral wall and the larger lying posteriorly inside the ramus of the jaw near the great vessels on a level with the first cervical vertebra. There were several fragments of metal scattered along the course of the bullet (Figs. 42 and 43).

The patient was given 10,000 units of perfringens antitoxin and 500 units of tetanus antitoxin. X-ray prophylaxis to the face for gas bacillus infection included five x-ray treatments in four days. He left the hospital on the eleventh day in good condition. The bullet fragments were not removed. Other treatment included sodium perborate irrigations, hot boric compresses to the right eye, oil of cloves to gums and 5 gr. empirin for pain. No sulfonamides were used. (See Figs. 41, 42, 43, pp. 207-209.)

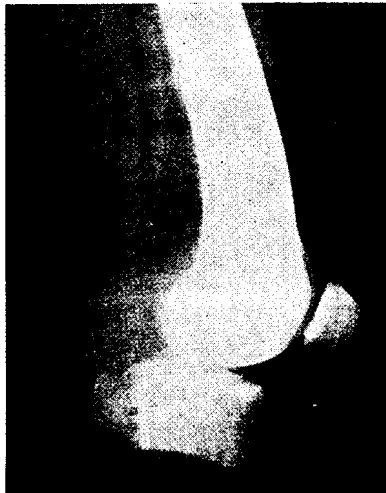

FIG. 39.—Same case as preceding, after amputation. The remaining fragment of the tibia is free of infection, thus giving a better functional result with use of the necessary artificial limb. Had osteomyelitis occurred, this proximal fragment of the tibia would have been lost.

of the second, third, fourth and fifth metacarpals. The x-ray film showed considerable gas in the tissues (Fig. 44), but whether this gas was introduced at the time of the injury or was the result of a gas bacillus infection was never determined. He received tetanus antitoxin and gas serum. Débridement was done. The hand was treated immedi-

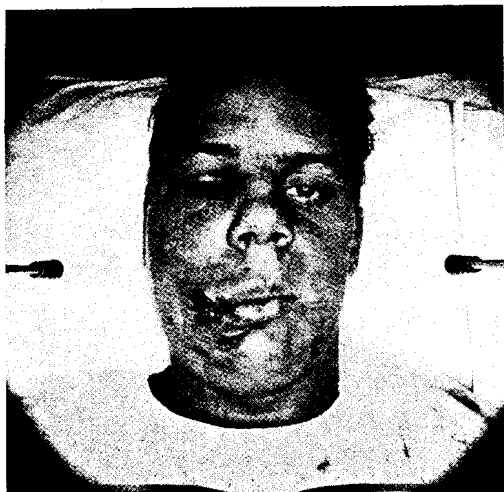

FIG. 41.—Case 17, p. 205. Photograph taken the second day after injury, showing the condition of the right side of the face and the wound of entrance at the right angle of the mouth.

ately with x-rays, twice daily for the succeeding two days and once on the third postoperative day. Temperature remained normal after this time. The patient was dismissed the tenth postoperative day. (See Figs. 44, 45, 46, pp. 210-212.)

This patient was treated promptly, and although he had an extremely severe wound with evidences of infection and fever, the temperature dropped promptly to normal (Fig. 46) and the soft tissues repaired rapidly. Osteomyelitis did not develop, as commonly happens with this injury. He received antitetanus and anti-gas serum, but no sulfanilamide. The attending clinicians thought x-ray irradiation was of definite value and lessened the period of hospitalization. Whether this case is listed as one of gas bacillus infection with recovery or as one in which x-rays were used as a prophylactic measure seems immaterial. The value of x-rays in hastening prompt recovery without mutilating surgery seemed evident to the clinicians who treated the patient. In this instance we have an example of the value of x-rays in

relieving the surgeon of any worry as to whether to wait or to amputate.

This is an example of a severe injury with considerable gas in the tissues in which x-ray treatment was given so early that

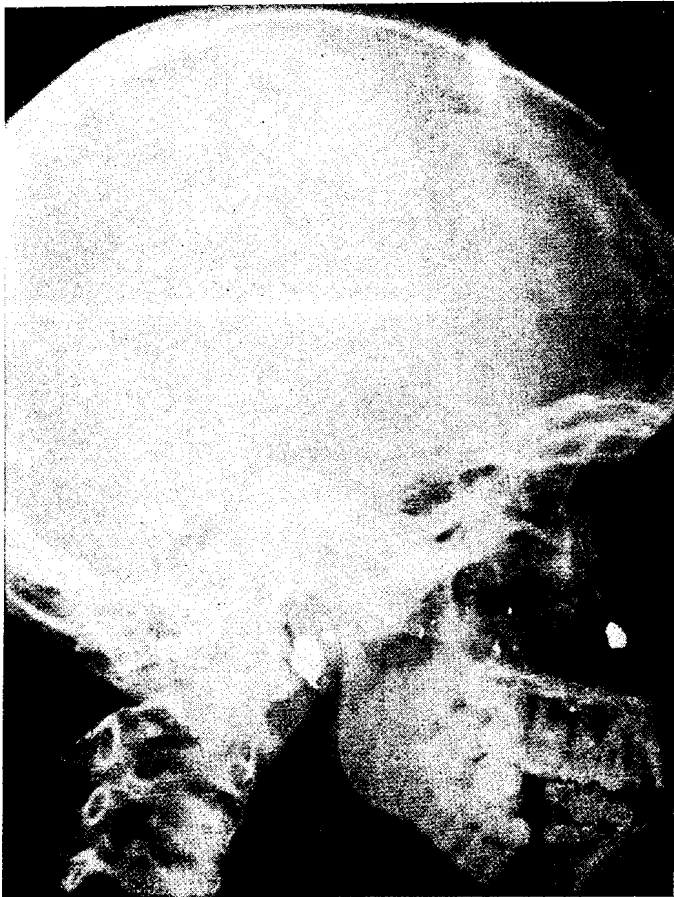

FIG. 42.—Same case as preceding. Lateral view of facial bones, showing wide distribution of bullet fragments with the main fragment lying near the great vessels of the neck.

it was impossible to state definitely that the patient had a gas bacillus infection. The fever, though low, was indicative of a beginning infection. At any rate, the outcome was more fortunate than that in Case 19, in which the injury was similar. It is better to be uncertain about the diagnosis and save the

hand than to be certain about the diagnosis and lose the hand. Some of the scientific accuracy in diagnosis demanded by a certain type of research worker who never treats a case of anything from one end of the year to the next does not always ap-

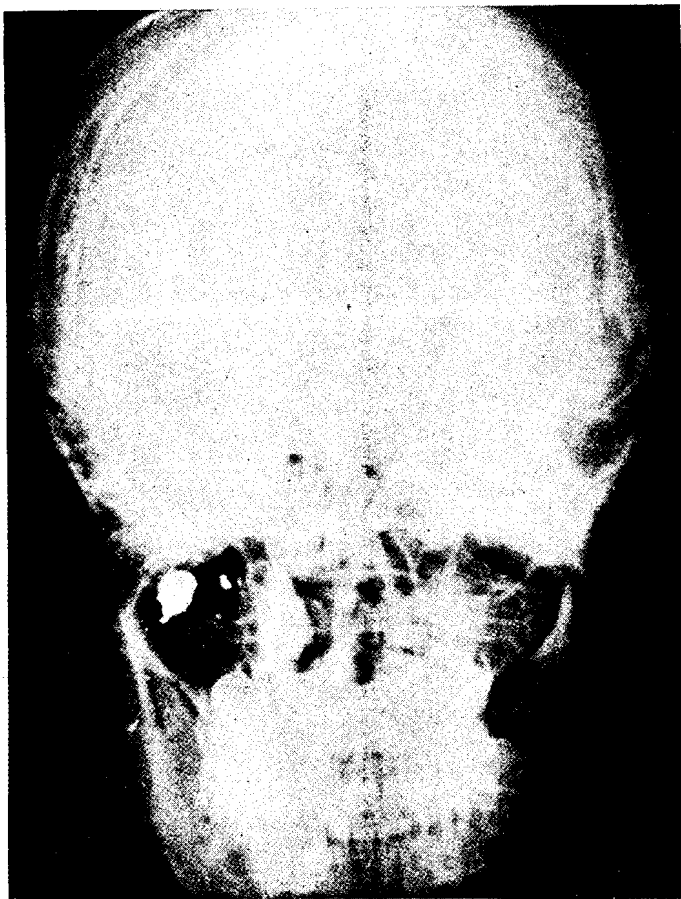


FIG. 43.—Same case as preceding. Postero-anterior view of facial area, showing wide distribution of bullet fragments from nasal septum in midline to outer wall of antrums; main fragment lies somewhat higher than its point of entrance at the angle of the mouth.

peal to the practitioner who has the responsibility of treating the patient.

It will be noted that more than the usual number of treatments recommended for prophylaxis were given in Case 18. This

was due to the fact that evidence of infection of some type was apparent. This is not listed as a case of gas bacillus infection as no cultures were made and the gas evident in the tissues might have been the result of the injury.

CASE 19.—H. T., a man aged 33, mangled his hand, with deep lacerations of the palmar surface and some crushing of the soft tissues.

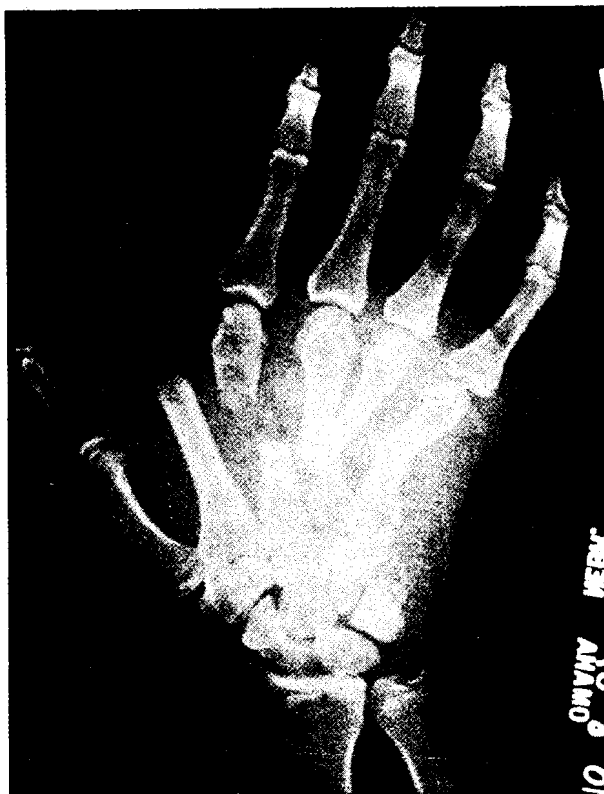

FIG. 44.—Case 18, p. 206. Severe injury to hand, multiple compound fractures and some gas in tissues (not cultured).

The wound was closed. Two days later the hand became discolored. Gas bacillus infection was apparent and gas serum was given. The patient was admitted to the hospital on the fourth day, when x-ray examination revealed considerable gas in the soft tissues and comminuted fractures of the metacarpals (Fig. 47). Amputation was performed 3 in. above the wrist, although gas was present in the axilla. After amputation, the patient received seven x-ray treatments in four

days over the stump, axilla and adjacent areas of the chest. He recovered. (See Fig. 47, p. 213.)

This patient is one of many who have had an amputation of an extremity through an area of infected tissues but who, with the aid of x-rays, recovered and retained the remainder of the extremity. Early administration of x-rays in such a case should

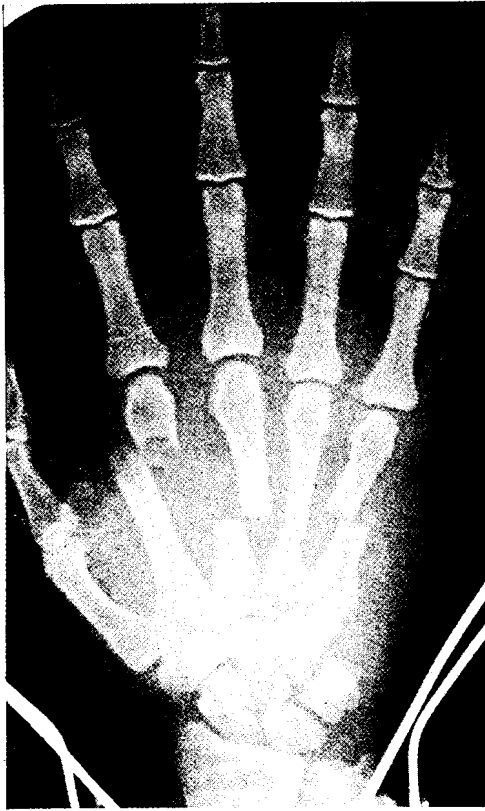


FIG. 45.—Same case as preceding, a few days later. No gas in tissues and osteomyelitis did not develop.

be a routine procedure, since it is a harmless measure when used prophylactically. In outlying districts where x-ray is not available, patients with injuries of this character should be transported immediately to the nearest hospital so that x-ray irradiation can be given before the tissues are necrotic. If one waits

until a rapidly progressing gas bacillus infection appears, complete destruction may take place before it is possible to reach the nearest institution for x-ray treatment. Such was the case of the patient, H. T., who undoubtedly would have benefited

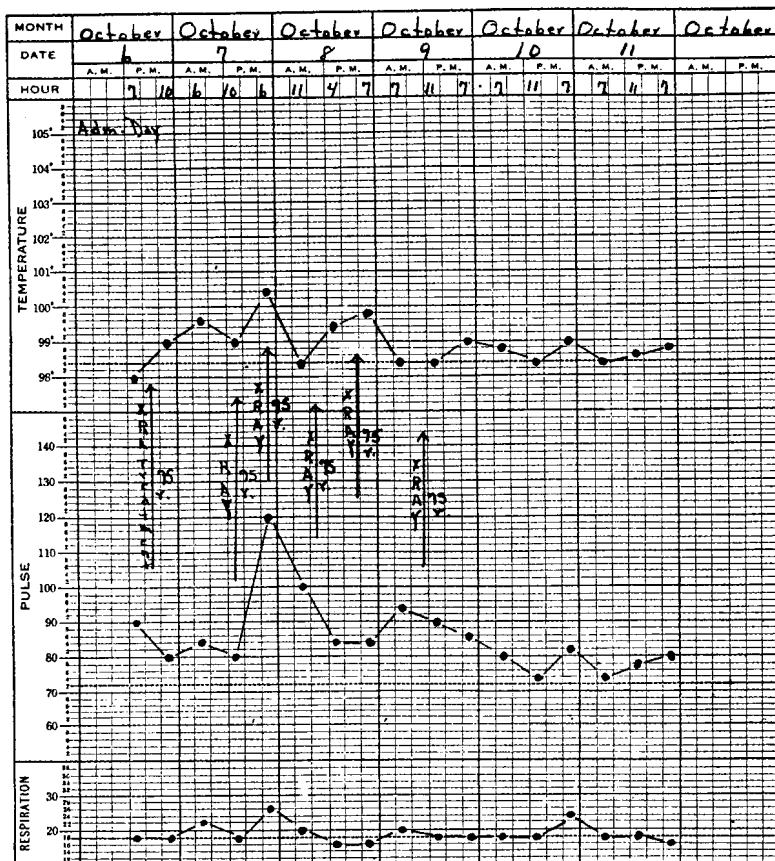


FIG. 46.—Same case as preceding. Excellent functional result was secured because of immediate x-ray therapy. The rise in pulse rate on the second day suggested the beginning of infection, but two treatments each day for two days terminated this threat.

from an emergency x-ray treatment in the small town where the accident occurred before he started his journey to Omaha. The best procedure, however, would have been x-ray prophylaxis immediately after the injury and before infection was evident (see p. 60 for emergency treatment).

Cases 18 and 19 should be compared in their management and their outcome.

CASE 20.—J. W., a man aged 53, had a gas bacillus infection in an injured left leg after the usual anti-gas and tetanus serums were given. He was also given a therapeutic dose of anti-gas serum and

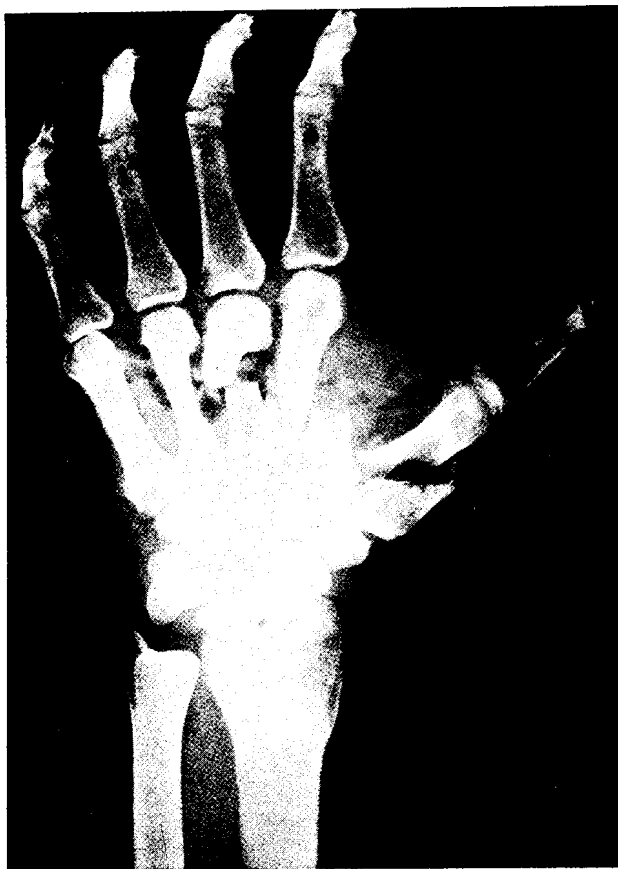


FIG. 47.—Case 19, p. 210. Type of injury similar to that in Case 18. Patient did not receive immediate x-ray therapy and consequently lost his hand.

12 x-ray treatments, 50 to 100 r each, over a nine day period. At this time, he was clinically free of evidence of gas bacillus infection. There was still evidence of infection with pyogenic organisms, and on the eighteenth day the left leg was amputated because of severe osteomyelitis. He died shortly afterward and autopsy showed necrosis and pockets of infection due to hemolytic streptococcus. There was no evidence of residual gas bacillus infection.

This case was placed in the doubtful group. It impressed us with the seriousness of the disease, in that many different organisms are generally present and one should not neglect any measure which will aid the patient in combating shock, loss of blood and other factors which tend to lower resistance. Early treatment, if at all possible, seems the important point in reviewing this case. This man lost first his leg and then his life as a result of secondary infection, and his was one of four cases of this type contained in our early reports. Three of these cases were seen in three different university teaching hospitals, and autopsies were performed, so the authenticity of the final diagnosis can hardly be doubted.

The point we are anxious to see decided in the next few years is whether or not the use of x-ray prophylaxis will prevent establishment of the secondary organisms in such injuries as these. If it proves possible to prevent these stubborn secondary organisms from initiating growth by prompt use of x-ray prophylaxis after the injury, a greatly lessened morbidity and even a slightly reduced mortality will result.

BASIS FOR CLINICAL EVALUATION OF THE METHODS

It is doubtful that much can be determined about the merits of either serum or x-rays in prophylaxis for gas bacillus infection, either in man with no evidence of gas bacillus infection or in experimental animals when they are treated before definite evidence of the disease is present. Nevertheless, if we accept as a basis for comparison of the prophylactic value *the effect of the two agents in treating the early stages of the disease in man*, x-rays seem definitely more effective. The early case in man seldom responds to serum, whereas x-rays will abort an early case of gas bacillus infection in man in a high percentage of cases. One may be justified, therefore, in claiming that they will prevent the development of the infection if they will abort it. Serum often fails to influence appreciably the course of the disease once it is established, and representative surgeons do not hesitate to amputate the diseased part, showing that from past experience they have little hope of completely controlling the disease with serum once the disease has developed. If it is permissible to draw any conclusion as to the relative efficiency of these

two agents in the parallel clinical condition of an early gas bacillus infection, the verdict must necessarily be rendered in favor of radiation as the preferable method of prophylaxis. The opinion of those who use x-rays in prophylaxis is emphatically in favor of the method. We feel that serum should not be given to the diabetic patients at any time either prophylactically or therapeutically.

SUMMARY

The foregoing cases show the value of x-rays as a means of prevention of gas bacillus infection. They vary from cases in which no infection was present to one case (Case 18) in which, although a positive diagnosis was not made, there was sufficient involvement to warrant classifying it among those of the early stage of the disease. The outcome in this case is compared to that in Case 19, with a similar injury but with loss of a hand, which probably could have been avoided if the patient had had x-ray prophylaxis or even early x-ray therapy.

The ease of application, the lack of complications and the possibilities of doing so much good should make x-rays a widely used agent for prevention of infection in recent, contaminated, severe injuries. Their use is indicated in every contaminated wound in which tetanus antitoxin is ordinarily given and we recommend this procedure. X-rays should be used promptly after the injury in the hope of preventing any and all types of organisms from establishing a growth.