

## Chapter XVIII

### ACUTE CONDITIONS IN THE ABDOMEN

In the discussion of x-ray therapy of appendicitis-peritonitis it was assumed that the diagnosis of each condition mentioned was correct, for it is important that before any patient is treated the diagnosis be reasonably certain. But in the diagnosis of acute intra-abdominal conditions—and appendicitis-peritonitis is such a condition—many possibilities must be carefully considered. A few of them are: appendicitis, appendicitis-peritonitis, functional postoperative distention, intussusception, internal hernia, mesenteric thrombosis, acute cholecystitis with and without calculi, renal colic, strangulated obstruction with and without gangrenous changes, pelvic and general peritonitis of uncertain origin, perforations and other more obscure intra-abdominal conditions.

Despite the great number of conditions to be considered by the radiologist, only three main groups exist. They are:

1. Conditions which will not require surgery for the present illness. It may be a matter of opinion whether or not x-ray therapy is indicated. If there is any evidence or suspicion of infection, x-rays should be used.

2. Conditions requiring immediate surgical intervention. If there is any suspicion of danger to the patient because of an infectious element found at operation, x-ray therapy should be started immediately after the operation. Or, if everything appears satisfactory at the operation and the patient suddenly shows evidence of infection a few days later, x-ray therapy should be started.

3. Conditions for which deferred surgical intervention is preferable. It is in this group that real danger may lie. If the diagnosis is appendicitis-peritonitis and the surgeon is of the school which waits for this process to localize before operating, he will obtain considerable aid from preoperative x-ray irradiation, for it will definitely lessen the toxemia and hasten localization, thus shortening the preoperative period. But if the condition is not appendicitis-peritonitis and surgery is deferred, for example, in the presence of an early gangrenous change in

### Diagnosis Uncertain

Our clinical experience with acute spreading peritonitis suggests that the use of x-ray therapy may result in as great a reduction in the mortality of this complication as of that of gas bacillus infection during the past 12 years. There may be this exception, however, that radical surgery, which is to be held to a minimum in the treatment of gas bacillus infection during the toxic stage of the disease, is encouraged during the early stages of peritonitis. This point will be discussed further, but its status is not likely to be decided for some time.

The status of x-rays in treatment of peritonitis of unknown origin will also be a matter for close study in the future. We have several cases of peritonitis other than appendicitis-peritonitis in which response was good, but they are too few to permit any conclusions.

In Case 42, the patient recovered without developing conclusive clinical symptoms, and as a result operation was not necessary and no definite diagnosis was made. When x-ray therapy was started the condition did not warrant an exploratory operation, and the patient improved so quickly with x-ray therapy that no reason for surgical intervention developed.

CASE 42.—G. H., a woman aged 49, was admitted to the hospital on August 8, 1938, with a temperature of 102 F., pulse rate 92 and respiratory rate 34. There was a history of a fall several days previously, but no injury was evident. The abdomen was rigid and markedly distended. A small bowel obstruction was suspected. The x-ray film showed a large amount of gas in the entire gastro-intestinal tract, but no evidence of a local obstruction. Treatment consisted of enemas, pitressin and the use of the suction apparatus, but the patient failed to improve. The axillary temperature on August 9 was 103.6 F.

On August 10 the attending physician asked for a consultation with the department of radiology. The patient was in an oxygen tent, cyanotic, comatose and greatly distended. The case looked hopeless. X-ray treatments were started immediately (Fig. 76). After four treatments of 75 r units given in three days, the abdomen was soft, and her condition remained good (Fig. 77, p. 282). She was dismissed from the hospital on August 19.

This case is unusual in that there were clinical signs of peritonitis, but etiology was not determined nor was definite diagnosis made. There was no operation and fortunately no autopsy, so the exact diagnosis never was made. The patient has had no recurrence of her trouble.

The problem of when to defer the operation and when to rely on x-rays is difficult. We have not had enough experience in treating cases in which surgery has not been resorted to to form an opinion, but we feel that surgical measures should be employed when there is any doubt about the exact outcome without

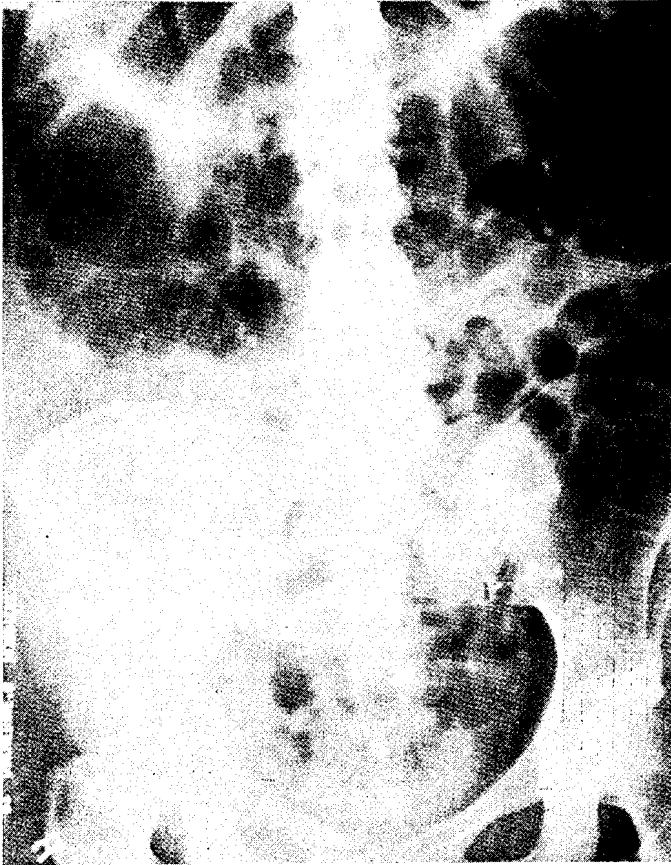


FIG. 76.—Case 42. Abdomen at time x-ray therapy was started.

surgery. In Case 42, the patient seemed to be a hopeless surgical risk and, therefore, we were justified in using only x-rays. But, if she had had an obstruction with an area of gangrenous intestine, the results would have been much different. Many experienced surgeons during the past 25 years have advocated a waiting period to permit better localization of pathologic pro-

cesses in certain types of appendicitis and peritonitis. It seems that x-rays should be of great help in localizing the process in this group of cases, as they undoubtedly have an inhibiting effect on some of the organisms usually present and are a definite aid in

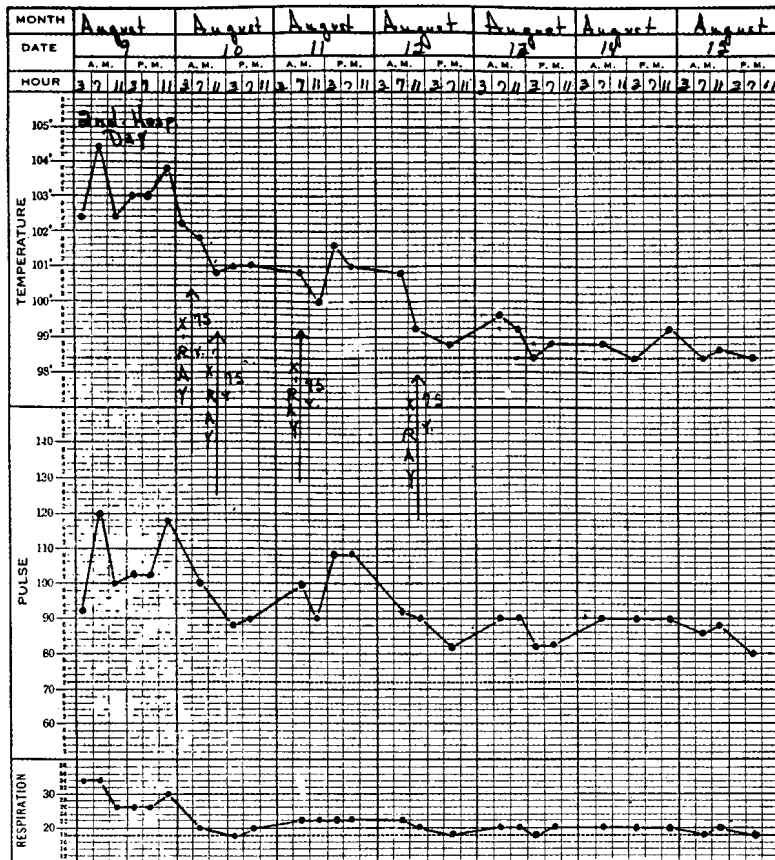


FIG. 77.—Same case as preceding. Immediate drop in temperature following beginning of x-ray therapy. Technical factors were: 110 kv.; 5 ma.; 40 cm. distance; 3 mm. Al filter; anterior abdomen as port. Result was excellent.

lessening toxemia. X-ray therapy also seems to be indicated in cases in which the process is too far advanced to warrant any surgical procedure without adding considerable risk to the patient's chances of recovery.

## CHANGING THE CHARACTER OF THE SURGICAL RISK

As x-ray therapy in some hopeless, inoperable cases of gas bacillus infection has carried the patient to a point where deferred amputation for a relatively strong patient was possible, so we feel that x-ray therapy in some hopeless cases of acute intra-abdominal infections may convert them into less toxic, safer, surgical risks. In Case 42 the only treatment which seemed to influence the toxemia was x-ray therapy, for immediately after it was started improvement was evident.

Obviously, one would regret giving radiation therapy to a patient with a gangrenous bowel or a strangulated obstruction which becomes gangrenous. The prompt differentiation of distention without obstruction from distention with obstruction, possibly caused by a strangulated gangrenous bowel, is definitely more important when x-ray therapy and the use of the suction tube are considered in preference to immediate surgery. Without obstruction, preoperative x-ray therapy and suction without surgery are indicated, but with obstruction, prompt surgical intervention combined with suction and x-ray therapy is indicated. However, when the condition is so far advanced that immediate surgery is out of the question, two x-ray treatments per day over the abdomen, use of the suction apparatus, oxygen tent and transfusions may convert a poor surgical risk into a good one or may make any surgical intervention unnecessary.

Cases 43 and 44 are representative of a group of patients apparently having pelvic peritonitis. The first patient was not operated on, was given x-ray therapy and promptly recovered. Diagnosis was not proved. In the second case, operation was performed immediately, the diagnosis was confirmed, the patient was given postoperative x-ray therapy and promptly recovered. The surgeon who prefers not to operate in the presence of acute peritonitis may follow the procedure in the first case; that followed in the second case is available to the surgeon who prefers to operate immediately. In both cases recovery was prompt and x-ray therapy seemed to be definitely beneficial.

CASE 43.—J. B. M., a woman aged 43, was admitted to the hospital March 21, 1939, with a history of low abdominal pain, vomiting and malaise. The white blood cell count was 20,260. The clinical diagnosis was acute bilateral salpingitis and pelvic peritonitis. X-ray therapy

with the mobile unit was instituted. She received 75 r units daily for four days. Surgery was not necessary. None of the sulfonamides was given. The temperature was normal on the fourth hospital day (Fig. 78). The patient was dismissed the ninth hospital day. The result was

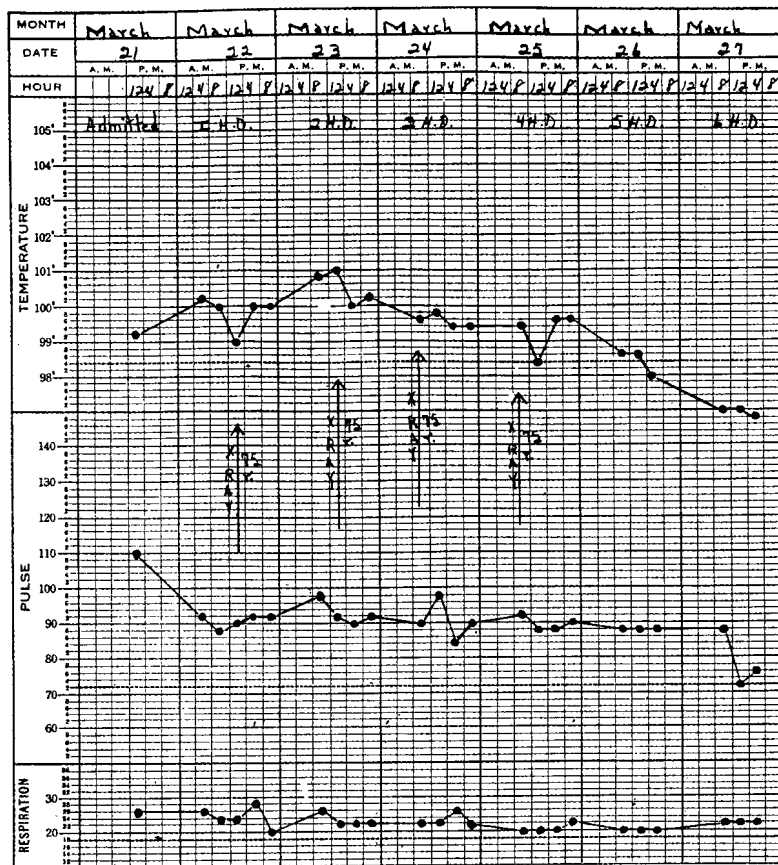


FIG. 78.—Case 43. Treatment was started early and response was prompt. It is better to be in doubt about the final diagnosis and have the patient recover in a few days than be certain about the diagnosis and have the patient hospitalized for several weeks. Technical factors were: 110 kv.; 5 ma.; 40 cm. distance; 3 mm. Al filter; anterior abdomen as port. Result was excellent.

considered highly satisfactory, although the diagnosis was purely clinical in the absence of a laparotomy.

The small doses of x-ray used in the treatment of acute inflammatory diseases should in no way be injurious to ovarian func-

tion. It seems that such treatment should be used as preliminary therapy for many acute pelvic inflammatory conditions, and surgery should be done when the condition becomes localized. In Case 43 surgery was not necessary, whereas in Case 44 the same

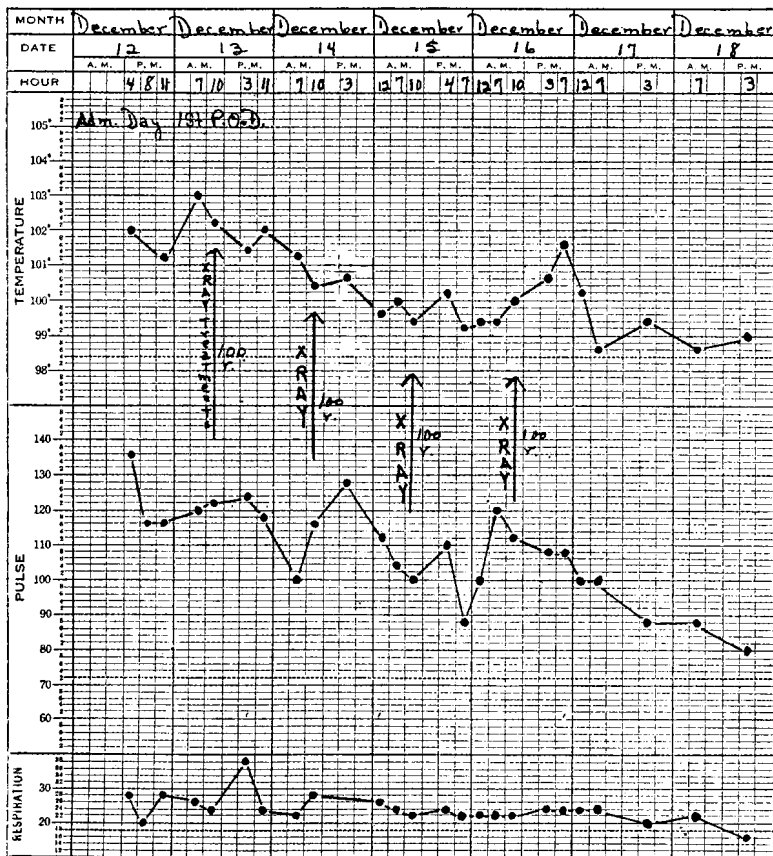


FIG. 79.—Case 44. Postoperative use of x-rays, as in this case, is an excellent way to expedite convalescence. Diagnosis was certain and response was prompt.

condition existed, but the patient was operated on immediately, received postoperative x-ray therapy and promptly recovered.

CASE 44.—M. G., a married woman aged 20, entered the hospital December 12, 1938, with a history of severe abdominal pain for eight days. Examination revealed marked tenderness throughout the abdomen, more severe in the lower portion. The white blood cell count

was 23,700, with 87 per cent polymorphonuclear leukocytes. Immediate laparotomy revealed bilateral salpingitis with about a quart of clear fluid in the pelvis. The appendix was congested secondary to the pelvic pathology. Bilateral salpingectomy and appendectomy were done. The temperature on the first postoperative day reached 103 F. X-ray therapy was ordered, and one treatment was given each day for four consecutive days. The temperature reached normal and remained so during an uneventful convalescence (Fig. 79). The patient was dismissed on the twelfth postoperative day.

This type of patient might be a safer surgical risk if x-ray therapy were given and followed by operation, but the surgeon who wishes to operate immediately will obtain considerable aid from x-ray therapy postoperatively in such cases. In fact, the element of fear of operating in this type of case is eliminated after a few experiences with postoperative x-ray therapy. If there is any question of choice between immediate and deferred operation, the surgeon should operate immediately and with considerable confidence since postoperative use of x-rays will almost certainly control the spread of the infection, as it did in Case 44.

#### DANGERS OF MASKING SYMPTOMS

The usual procedure is to institute suction therapy as soon as there is evidence of peritoneal irritation. We attribute to the suction apparatus, which places the intestine at rest, the early control of the situation in most instances. In fact, many stubborn partial or temporary obstructions have seemed to respond to the use of the suction apparatus alone. X-rays, too, have occasionally been used alone, and patients with distention and fever of obscure etiology have promptly recovered.

We do not advocate the long-continued use of the suction apparatus to decompress and quiet the bowel or repeated x-ray treatments to lessen the evidence of infection in the peritoneum in uncertain cases. In such circumstances, a hopeless gangrenous condition of the bowel might develop with few symptoms. We had such an experience, described in the following case.

CASE 45.—A youth, aged 19, had severe peritonitis at the time he was operated on for acute appendicitis with perforation. The appendix was removed and a drain inserted. He responded satisfactorily to x-ray treatments given the second, third and fourth postoperative days, the peritonitis subsiding. The drainage tube was removed from the incision the fifth day postoperatively. Four days later there was evidence

of intra-abdominal involvement with a rise in temperature (Fig. 80). The suction apparatus and x-rays were called into service and the temperature immediately subsided. However, the patient did not do very well, vomiting promptly each time the suction apparatus was removed, although the temperature did not go very high. Reoperation was considered but not carried out because of the virulent peritonitis present

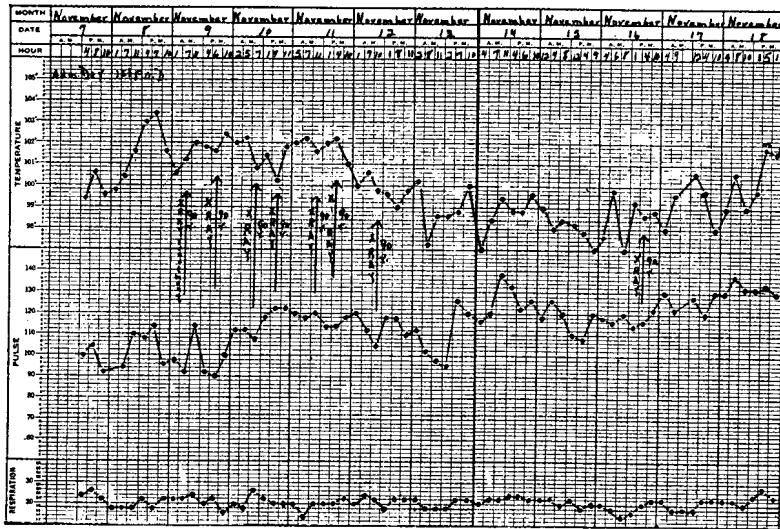


FIG. 80.—Case 45. Early favorable response, but later relapse due to incarceration of the bowel in the incision when the drainage tube was removed. Technical factors were: 110 kv.; 5 ma.; 50 cm. distance; 3 mm. Al filter; anterior abdomen as port. Result was poor.

at the time of operation. The patient died the seventh day after removal of the drainage tube.

Postmortem examination revealed a loop of small bowel herniated into the incision, apparently having slipped into this position when the drainage tube was removed. Only a small area of residual peritonitis was seen, near the incision. The cause of death was given as intestinal obstruction and peritonitis.

The important point in this case is that through the combined use of the suction apparatus and x-rays the usual symptoms—distention, vomiting, elevation of temperature—and other signs of obstruction and infection with toxemia were minimized and the true state of affairs was misinterpreted.

On another occasion, we treated a young woman adequately, but she died about the fifth day, and postmortem examination revealed the abdomen full of free pus. There had been little

drainage through the rather small incision made in the culdesac.

These cases suggest that when the response to radiation therapy and the suction apparatus is not decisive and does not give some signs of permanence within 48 hours, surgical intervention may best be employed; otherwise a serious situation may develop which cannot possibly be met by the use of x-rays or suction apparatus.

This young woman was not treated with x-rays until the process was in the fibrinopurulent stage, and the excessive amount of free pus seen on postmortem examination made it evident that x-rays do not drain pus from closed cavities. In Case 45, it was evident that x-rays do not free strangulated hernias.

The object of this discussion is to emphasize the importance of an early and accurate diagnosis and a willingness to change the diagnosis as the clinical evidence indicates such a necessity. If no improvement is evident after the third or at least the fourth x-ray treatment, surgical intervention should be given the greatest consideration. Freeing the loop of strangulated bowel in one case and free drainage of the peritoneal cavity in another might have saved the patients.

#### MOST SUITABLE TIME FOR OPERATION IN ACUTE ABDOMINAL CONDITIONS

In a case of appendicitis with a possibility of early peritonitis, the literature shows the best surgical opinion divided concerning the proper time to operate—immediately or later. Such division of opinion usually indicates that no plan has worked with consistent success. When one group of prominent surgeons recommends immediate operation on a patient with appendicitis even in the presence of early peritonitis and others of equal prominence caution against immediate operation in the same circumstances, there must be some reason for such a difference in opinion. However, we are not so much interested in the problem of immediate or delayed operation as we are in advocating the early use of x-ray therapy, regardless of which procedure the surgeon follows.

In the case in which immediate operation is deemed necessary, x-ray irradiation over the abdomen every eight hours or at

least every 12 hours for five to eight doses, starting promptly after operation, will definitely lower the mortality and morbidity, even if generalized peritonitis is encountered.

In the delayed operation group, we have had patients with a diagnosis of peritonitis who were considered too ill for immediate operation. They were given only radiation therapy, responded promptly and remained well without operation. We do not recommend that surgery be omitted.

We have also had patients in the same group, apparently too ill for immediate operation who were given x-ray therapy, operated on later and had no trouble of any consequence. This is the preferable procedure following preoperative irradiation.

We have also had patients for whom the surgeon elected to defer operation. X-ray treatments were given, but the patients died of strangulated gangrenous bowel, open perforated ulcers and undrained generalized purulent peritonitis.

Therefore selection of the time of operation resolves itself into a matter of surgical judgment; x-ray therapy is recommended only as an aid to the surgeon in the battle against the infectious element of the disease. The Wangenstein suction apparatus, on the other hand, is an aid to the surgeon primarily in the battle against the mechanical elements involved in the disease. Both x-rays and the suction apparatus, therefore, may be used pre- and postoperatively to increase the patient's chance of recovery, but neither will overcome many of the essentially surgical conditions encountered in acute conditions in the abdomen.

Every possible effort should be made to achieve a correct diagnosis, particularly by means of  $14 \times 17$  x-ray films of the abdomen. X-ray study with and without a small amount of barium has been advocated for the past 25 years by Case and others. An article by Case<sup>12</sup> published in 1938 is worthy of study.

In our cases, the risk of operation in the presence of spreading peritonitis has been definitely lessened by using x-ray therapy, treating at eight hour intervals starting immediately after operation, or by giving some treatments before operation. We might summarize by suggesting the following plan. If in doubt, operate immediately and rely on x-rays to aid in controlling the peritonitis, always keeping in mind that each case presents an individual clinical problem. Certainly no fixed laws can be established when dealing with such a complex problem as acute

involvement of the abdomen. Much more will be learned about the effect of irradiation therapy in the infections involving the abdominal and pelvic viscera in the next few years, but clinical judgment will always be the essential requirement for success.

#### PROPHYLAXIS

X-rays may be said to be employed for prophylaxis against peritonitis when given: (1) preoperatively on the basis of findings warranting a tentative diagnosis of appendicitis prior to definite involvement of the peritoneum; (2) postoperatively following the removal of an acutely involved appendix when no great amount of involvement of the peritoneum was present at the time of operation, and (3) after injuries perforating the intestines and the patient is irradiated immediately after admission to the hospital, before peritonitis has developed.

#### PERFORATED BOWEL

In all cases of perforation of the bowel, particularly those due to a stab or gunshot wound, pre- and postoperative x-ray treatments are indicated. Control of the infectious element of this clinical problem is greatly simplified by this procedure. It should be especially valuable in military and industrial injuries.

CASE 46.—R. T., a man aged 36, entered the hospital March 30, 1941, complaining of severe abdominal pain of seven hours' duration. Symptoms were coincident with the formation of an irreducible hernial mass in the right inguinal area. Immediate surgery revealed a loop of small bowel (ileum) adherent to the hernial sac. There was a perforation 0.5 cm. in diameter in one loop. The bowel was reduced and the perforation sutured.

X-ray therapy was started immediately after surgery, three treatments being given the day x-ray therapy was started, two treatments the following day and one treatment a day for the next two days. The suction tube was also used. The patient made a rapid recovery, leaving the hospital the twentieth postoperative day. No sulfonamides were given.

Examination of the temperature chart (Fig. 81) during the first week shows the usual course when a patient with this type of condition is given prompt x-ray treatment. On the second day the patient had a chill with an increase in pulse rate, but the temperature and pulse rate dropped steadily each day, until at the end of the first week both temperature and pulse rate were practically normal. The chill and early

elevation of both temperature and pulse rate suggest that severe peritonitis might have developed had not x-ray therapy been used. (See also Case 47.)

When x-ray therapy is used as suggested in such cases as these, no confusing symptoms ever arise, whereas when the sulfon-

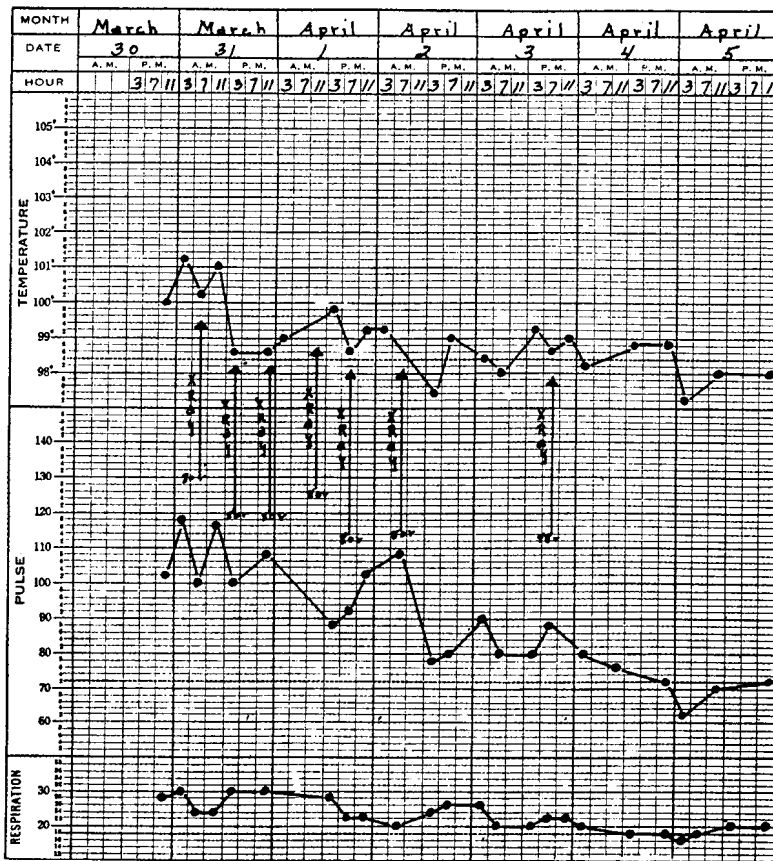


FIG. 81.—Case 46.

amides are used, a variety of symptoms, usually of minor significance, do arise and may cause the family as well as the clinician considerable anxiety.

CASE 47.—A. K., a youth aged 18, entered the hospital at 7:10 P. M., June 3, 1941, three hours after receiving a gunshot wound in the abdomen. There was little bleeding from the wound, and he had

Best results were obtained in cases of acute puerperal infection. This is contrary to the experience reported by some authors, who advise against using the rays in acute febrile cases. The author did not find the results any poorer in gonorrhoeal cases, as some authors have reported. There were only 2 cases in which the inflammation was aggravated. One special advantage of the treatment is the rapid and complete control of pain which makes it possible to institute local treatment. Several days are gained in this way. One case is mentioned in which irradiation brought about such marked improvement in the general condition and reduction of the exudate that a cyst could be diagnosed and operated on successfully.

Comparing the results obtained with those obtained by medical treatment alone, the time required for cure is considerably less in the irradiated cases. The roentgen treatment was associated with medical treatment and rest which were also factors in the cure.

The treatment is particularly indicated in septic puerperal processes. In these and the acute forms of inflammation of the adnexa it should be given as early as possible. It is less effective in chronic cases.<sup>15</sup>

Our observations were made independently, but with the exception of some technical details they are in full accord with the conclusions of these workers. They use a longer space factor and heavier filtration with fewer treatments than we have used. It is certain that the earlier treatments are started, the more satisfactory the results, and that treatments in the chronic stages are of less value. The lowered cost of care as a result of early treatment was noted by Fried and Bertolotto.

We consider a short space factor essential in the fulminating type of infections with a high mortality, such as gas bacillus infection, but the space factor and also the dose per treatment and total dosage are still subject to much clinical experimentation and observation.

#### SUMMARY

From the time of our first attempts to treat acute peritonitis with x-rays we have been impressed by the prompt response we were able to secure. In fact, our first patient, treated in the summer of 1934, responded as dramatically as did the first patient with gas bacillus infection.

We feel that the mortality rate can be reduced at least to 10 per cent or possibly more for appendicitis-peritonitis if x-ray treatment becomes more generally used in the early stage and sulfanilamide is not given simultaneously with x-rays.

Statistics on peritonitis, as on gas bacillus infection, do not seem to us as important as the clinical evidence of favorable therapeutic response which is so obvious to any who observes

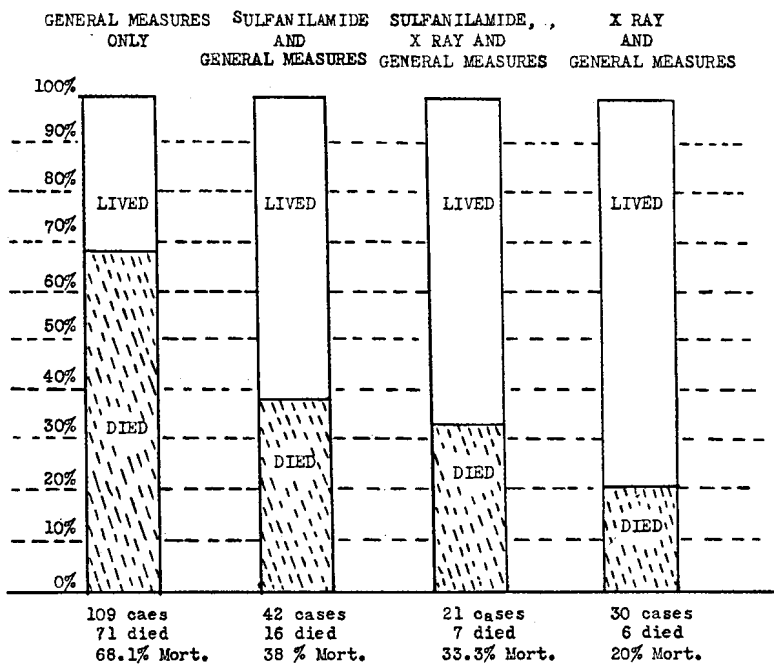


FIG. 83.—Mortality rate in cases of general peritonitis following appendicitis treated by various measures. Note drop in mortality rate when x-ray therapy is used.

a case treated with x-rays. It is hoped that adoption of x-ray therapy of acute peritonitis will be more rapid than was the case for gas bacillus infection.

CONCLUSIONS

Our experience with x-ray therapy of gas bacillus infection and acute spreading peritonitis leads us to believe that x-rays have an almost specific action in these infections. Someday, all may be satisfied to wait for the acute spreading peritonitis to localize before operating. However, until the wisdom of this procedure is fully determined, we are not attempting to influence the surgeon as to the time operation should be performed.

For the surgeon who prefers to wait, the use of x-rays is indicated because they will shorten that waiting period and make localization more certain. The surgeon who believes in early operation may follow his convictions but should use x-ray therapy beginning immediately after operation. The addition of x-ray therapy to either routine will undoubtedly lower the mortality for all types of cases, including those with a relatively clean appendix in which occasionally serious if not fatal peritonitis develops as well as those in which there is definite peritonitis when first seen. X-ray treatment of the acutely infected peritoneum will lower the mortality for laparotomies performed for all purposes—in cases infected before operation and in those not showing evidence of peritonitis until after operation.

We can influence the clinical course of the patient who has gas bacillus infection and feel confident that x-rays have a similarly beneficial effect on many acute, peritoneal infections which, according to many, are often due to the same group of organisms as that found in gas bacillus infection.

The use of the suction apparatus has greatly increased the necessity for a more exact preoperative diagnosis than was required in the past. The addition of x-rays is certain to emphasize further the necessity for prompt, correct diagnosis. The indications for drainage or the omission of drainage after operation for a ruptured appendix may also be affected through the use of x-rays in controlling the infection.

In the entire discussion we have attempted to make it clear that x-ray therapy is urgently recommended for intra-abdominal infection but that there still exists the same number of conditions which, as formerly, requires prompt diagnosis and expert surgical intervention. X-rays are recommended as an aid before and after operation, but not as a substitute for operation. Organic obstruction must be relieved, pus pockets must be drained, gangrenous and otherwise diseased organs and tissues must be removed, and other conditions requiring surgical intervention must be recognized and properly managed.

## BIBLIOGRAPHY FOR PART IV

1. Manges, W.: Personal communication.
2. Welch, W. H.: "Morbid Conditions Caused by Bacillus Aërogenes Capsulatus," Bull. Johns Hopkins Hosp. 11:185, 1900.
3. Welch, W. H., and Flexner, S.: "Observations Concerning the Bacillus Aërogenes Capsulatus," J. Eper. Med. 1:5, January, 1896.
4. Veillon and Zuber: "Recherches sur quelques microbes strictement anaérobies et leur rôle en pathologie," Arch. d. méd. expér. d'anat. path. 10:517, July, 1898.
5. Williams, B. W.: "Importance of Toxemia Due to Anaerobic Organisms in Intestinal Obstruction and Peritonitis," Brit. J. Surg. 14:295, October, 1926.
6. Michel, D. G.: Congr. internat. de chir. 6:272, 1923.
7. Bower, J. O.: "Spreading Peritonitis Complicating Acute Perforative Appendicitis," J. A. M. A. 112:11, Jan. 7, 1939.
8. Weinberg, M., and Prévot, A. R.: "De l'emploi des anatoxines pour la préparation des serums antigangreneux," Compt. rend. Acad. d. Sc. 179:227, July 21, 1924.
9. Altmeier, W. A.: "The Bacterial Flora of Acute Perforated Appendicitis with Peritonitis," Ann. Surg. 107:517, April, 1938.
10. Walters, W., and Snell, A. M.: *Diseases of the Gallbladder and Bile Ducts* (Philadelphia: W. B. Saunders Company, 1940), p. 128.
11. Thompson, W. D., et al.: "Use of Lyophile Plasma in Correction of Hypoproteinemia and Prevention of Wound Disruption," Arch. Surg. 36:509, March, 1938.
12. Case, J. T.: "Value of X-Ray Study in Acute Bowel Obstruction," Illinois M. J. 74:326, October, 1938.
13. Fried, C.: "Die Röntgenbestrahlung akuter und subakuter eitriger Entzündungen," Acta radiol. 9:109, 1928.
14. Fried, C.: "Röntgenbehandlung entzündlicher Beckenerkrankungen in der Gynäkologie," Strahlentherapie 19:649, 1925.
15. Bertolotto, U.: "La röntgenterapia nelle forme infiammatorie ginecologiche," Radiol. med. 21:1103, October, 1934.

